

DOI: <https://doi.org/10.17816/DD430154>

# Магнитно-резонансная томография в диагностике редкого генетического заболевания — недержания пигмента (синдром Блоха–Сульцбергера) — на примере клинического случая

И.И. Ярмола<sup>1</sup>, А.В. Аникин<sup>1</sup>, Д.А. Ганькин<sup>2</sup>, Л.Е. Фомина<sup>1</sup>, Н.А. Харитоновна<sup>1</sup>, И.С. Жанин<sup>1</sup>, А.А. Пушков<sup>1</sup>, М.А. Басаргина<sup>1</sup>, О.Б. Кондакова<sup>1</sup>

<sup>1</sup> Национальный медицинский исследовательский центр здоровья детей, Москва, Российская Федерация;

<sup>2</sup> Щёлковский перинатальный центр, Щёлково, Российская Федерация

## АННОТАЦИЯ

Недержание пигмента (синдром Блоха–Сульцбергера) — редкое наследственное заболевание, проявляющееся характерными кожными высыпаниями и поражением других органов и систем. Магнитно-резонансная томография является приоритетным методом для визуализации структурной патологии головного мозга и прогноза неврологической манифестации у ребёнка.

Ключевая роль диагностики заболевания недержания пигмента принадлежит дерматологу; подтверждающая диагностика проводится путём молекулярно-генетического анализа гена *IKBKG*.

В представленном клиническом наблюдении у новорождённой девочки с высыпаниями на кожных покровах, типичными для синдрома Блоха–Сульцбергера, и выявленной делецией в гене *IKBKG* проводилась магнитно-резонансная томография головного мозга, где были обнаружены многочисленные очаги ишемии, кровоизлияния и поражение проводящих путей.

Магнитно-резонансная томография головного мозга у пациентов с синдромом Блоха–Сульцбергера используется для оценки тяжести поражения вещества мозга, что позволяет объяснить причину неврологических симптомов, скорректировать реабилитационные мероприятия, а также прогнозировать развитие ребёнка.

**Ключевые слова:** недержание пигмента; синдром Блоха–Сульцбергера; магнитно-резонансная томография; дегенерация проводящих путей; ген *IKBKG*.

## Как цитировать:

Ярмола И.И., Аникин А.В., Ганькин Д.А., Фомина Л.Е., Харитоновна Н.А., Жанин И.С., Пушков А.А., Басаргина М.А., Кондакова О.Б. Магнитно-резонансная томография в диагностике редкого генетического заболевания — недержания пигмента (синдром Блоха–Сульцбергера) — на примере клинического случая // *Digital Diagnostics*. 2023. Т. 4, № 3. С. 384–392. DOI: <https://doi.org/10.17816/DD430154>

DOI: <https://doi.org/10.17816/DD430154>

# Magnetic resonance imaging for diagnosing a rare disease: incontinentia pigmenti (Bloch–Sulzberger syndrome) on the example of a clinical case

Igor I. Yarmola<sup>1</sup>, Anatoly V. Anikin<sup>1</sup>, Dmitry A. Gankin<sup>2</sup>, Lyubov E. Fomina<sup>1</sup>, Nataliya A. Kharitonova<sup>1</sup>, Ilya S. Zhanin<sup>1</sup>, Alexander A. Pushkov<sup>1</sup>, Milana A. Basargina<sup>1</sup>, Olga B. Kondakova<sup>1</sup>

<sup>1</sup> National Medical Research Center for Children's Health, Moscow, Russian Federation;

<sup>2</sup> Shchelkovsky Perinatal Center, Schelkovo, Russian Federation

## ABSTRACT

Incontinentia pigmenti, also known as Bloch–Sulzberger syndrome, is a rare hereditary disease characterized by typical skin rashes and involvement of other organs and systems. Magnetic resonance imaging stands as the primary method for visualizing the structural pathology of the brain and predicting neurological manifestations in an affected child.

Diagnosing incontinentia pigmenti predominantly falls within the domain of dermatologists; verification is performed by molecular genetic analysis of the *IKBKG* gene. This study involved magnetic resonance imaging of the brain in a patient with skin rashes, characteristic of Bloch–Sulzberger syndrome, and deletion in the *IKBKG* gene, where numerous foci of ischemia, hemorrhages, and lesions of the tracts were detected.

Magnetic resonance imaging of the brain in patients with Bloch–Sulzberger syndrome is used to evaluate the severity of damage to the brain substance, which makes it possible to explain the cause of neurological symptoms and correct habilitation, as well as predict the development of the child.

**Keywords:** incontinentia pigmenti; Bloch–Sulzberger syndrome; magnetic resonance imaging; white matted tracts degeneration; *IKBKG* gene.

## To cite this article:

Yarmola II, Anikin AV, Gankin DA, Fomina LE, Kharitonova NA, Zhanin IS, Pushkov AA, Basargina MA, Kondakova OB. Magnetic resonance imaging for diagnosing a rare disease: incontinentia pigmenti (Bloch–Sulzberger syndrome) on the example of a clinical case. *Digital Diagnostics*. 2023;4(3):384–392. DOI: <https://doi.org/10.17816/DD430154>

Received: 16.05.2023

Accepted: 29.06.2023

Published: 22.08.2023

DOI: <https://doi.org/10.17816/DD430154>

# 磁共振成像在罕见遗传性疾病（即色素失禁症，也称布洛赫-苏兹伯格综合征）诊断中的应用：临床病例

Igor I. Yarmola<sup>1</sup>, Anatoly V. Anikin<sup>1</sup>, Dmitry A. Gankin<sup>2</sup>, Lyubov E. Fomina<sup>1</sup>, Nataliya A. Kharitonova<sup>1</sup>, Ilya S. Zhanin<sup>1</sup>, Alexander A. Pushkov<sup>1</sup>, Milana A. Basargina<sup>1</sup>, Olga B. Kondakova<sup>1</sup>

<sup>1</sup> National Medical Research Center for Children's Health, Moscow, Russian Federation;

<sup>2</sup> Shchelkovsky Perinatal Center, Schelkovo, Russian Federation

## 简评

色素失禁症（布洛克-苏兹伯格综合征，Bloch-Sulzberger Syndrome）是一种罕见的遗传性疾病，表现为特征性皮炎以及其他器官和系统的损坏。磁共振成像是显示出大脑结构病变和预测儿童神经系统表现的优先方法。

皮肤科医生在色素失禁症的诊断中起着关键作用；需要通过对IKBKG基因进行分子遗传分析，以确诊。

一名新生女婴患有典型的布洛赫-苏兹伯格综合征皮炎和IKBKG基因缺失，在进行脑磁共振成像检查后，医生发现了多处缺血、出血和传导通路病变。

布洛赫-苏兹伯格综合征患者的脑磁共振成像可用于评估脑物质损坏的严重程度，这有助于解释神经症状的原因、调整康复措施和预测患儿的发展。

**关键词：**色素失禁症；布洛克-苏兹伯格综合征；磁共振成像；传导通路变性；IKBKG基因。

## 引用本文：

Yarmola II, Anikin AV, Gankin DA, Fomina LE, Kharitonova NA, Zhanin IS, Pushkov AA, Basargina MA, Kondakova OB. 磁共振成像在罕见遗传性疾病（即色素失禁症，也称布洛赫-苏兹伯格综合征）诊断中的应用：临床病例. *Digital Diagnostics*. 2023;4(3):384-392.

DOI: <https://doi.org/10.17816/DD430154>

收到: 16.05.2023

接受: 29.06.2023

发布日期: 22.08.2023

## 现实性

色素失禁症 (OMIM 308300: 布洛赫-苏兹伯格综合征, 色素失禁症, II型) 是一种罕见的X连锁遗传病, 属于遗传性皮肤病。该病的特征是皮肤、毛发、牙齿、指甲、眼睛和中枢神经系统出现病变。该病大多在婴儿出生后的头几天或几周内发病。

世界文献中描述的色素失禁症病例已超过2000例。病例数量还在继续增加。据估计, 全球色素失禁症的发病率为每100万人中有0.7例。欧洲的发病率为每10万名新生儿中有1.2例[1]。该病是由位于X染色体长臂Xq28位点上的IKBKG基因 (B细胞κ轻链基因增强子抑制因子) 的致病突变引起的。该基因参与细胞凋亡、细胞周期、炎症、免疫和其他途径的调控[2-4]。

这种疾病的特点是临床多态性, 即从生活质量的轻微下降到致命病例。该基因的致病核苷酸变异会导致大脑结构发生变化[5]。这些异常可通过磁共振成像 (MRI) 检测到。磁共振成像还可被用于诊断其他单基因[6]和多因素[7]遗传病。

该病为X连锁显性遗传。大多数男孩在胚胎发育期间就会因这种疾病而死去。患病女孩与男孩的比例为20:1。

色素失禁症患者的器官和系统会出现多处病变, 主要是从外胚层板发展而来。100%的病例都会出现皮疹。皮疹是多发性的。一个明显的特征是水泡和脓疱呈线状排列 (沿布拉什可氏线)。色素失禁症患者会出现脱发、牙齿畸形、指甲营养不良, 并且眼睛病变 (视网膜血管过度扩张) 的风险也会增加; 视网膜血管过度扩张如不及时治疗, 可能会导致视网膜脱离 (通常, 这类患者视网膜脱离发生在6岁之前) [8]。斜视、白内障、视神经萎缩、视网膜色素病变和小眼症也很常见。根据不同学者的研究, 10%-30%的病例中, 色素失禁症会影响中枢神经系统[9]。中枢神经系统损害表现为不同程度的抽搐 (从单一癫痫发作到慢性癫痫都有描述)、认知障碍、发育迟缓和痉挛性轻瘫。乳房发育不全、多乳头、原发性肺动脉高压、白细胞增多和其他罕见病症则较少见。

该病通过分子遗传学检测方法诊断, 以检测IKBKG基因中的致病基因变异。该病也可通过皮肤活检标本的组织学检查确诊。临床标准也允许怀疑色素失禁症[10]。

治疗属于对症预防性质。治疗的目的是预防皮肤感染、视网膜脱落、癫痫发作。如果牙齿有病变, 则需要植入假牙和矫正牙齿形状; 如果出现痉挛或轻瘫, 则需要进行治疗。

## 病例描述

新生儿L (女孩) 出生14天, 在俄罗斯联邦卫生部“国家儿童健康医学研究中心”联邦国家自治机构 (Federal State Autonomous

Institution “Scientific Center of Children’s Health” of the Ministry of Health of the Russian Federation, FSAI “SCCH” of the Ministry of Health of the Russian Federation) 新生儿和幼儿病理学部住院治疗。

**产前病史。**由于母亲在第一个孕期感染了巨细胞病毒 (经聚合酶链反应证实), 妊娠在第一和第二个孕期面临终止。母亲接受了住院治疗。在第三个孕期, 母亲曾三次感染急性呼吸道病毒, 两次出现疱疹。

二胎, 足月, 自然分娩, 胎龄38周。婴儿出生体重3470g, 身高53cm, 阿普加评分9/9分。

**出生后,**孩子的总体状况令人满意。孩子的躯干、面部和四肢都出现了广泛的疹病 (图1)。头皮部位没有皮疹。根据年龄, 实验室检查值在正常值范围内。没有炎症指标。

从生命的第四天开始, 全身状况开始恶化: 腿部和手臂出现发绀的斑点, 皮肤呈灰白色, 呼吸减弱并有呼吸急促的趋势, 血氧饱和度低 (饱和度, SpO<sub>2</sub>) ——81-95%, 检查时出现过度兴奋, 休息时意识减退, 上下肢肌肉张力过高, 头向后仰, 抽搐。

血液检测结果中发生了变化: 血液酸碱度 (pH值) 降至7.242, 血乳酸增至6.4mmol/L, 碳酸氢盐浓度 (HCO<sub>3</sub><sup>-</sup>) 降至16.7mmol/L (代谢性酸中毒)。

在皮肤科医生的检查中, 发现了皮肤病灶呈动态消退, 并形成褐色和浅粉色的线状色素沉着。进一步观察发现了, 色素沉着向色素减退过渡。初步诊断为: “布洛赫-苏兹伯格综合征”。

**分子遗传学检查**的目的是寻找IKBKG基因中第4-10号外显子的缺失。使用M.N.Haque等人的文

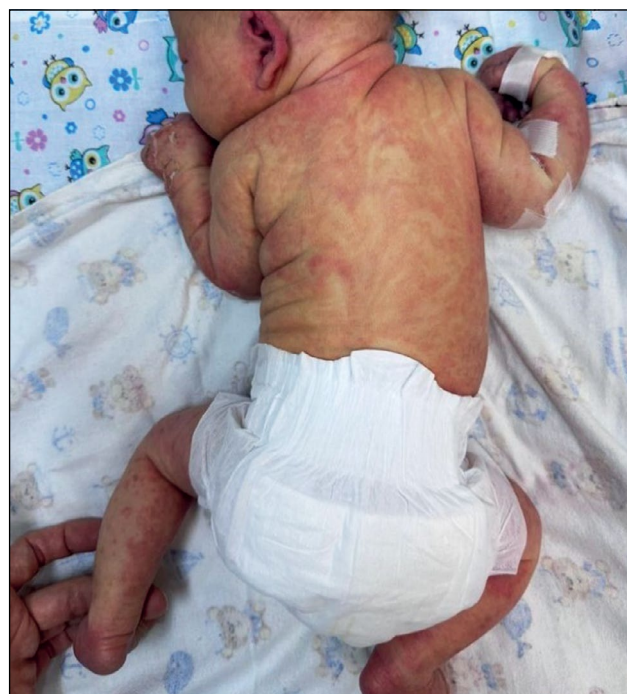

图1. 沿布拉什可氏线扩散的水泡。

章[11]中描述的引物,采用了多重等位基因特异性聚合酶链反应方法。检查发现了,IKBK<sub>G</sub> 基因中第4-10号外显子存在杂合性缺失。人类基因突变数据库(Human Gene Mutation Database (HGMD) Professional)描述了布洛赫-苏兹伯格综合征患者的IKBK<sub>G</sub>基因第4-10号外显子的杂合性缺失。这种核苷酸变异是色素失禁症最常见的变异之一,发生在65%的患者中[12]。

出生后第四天,孩子的病情被评估为中重度,因为出现中枢神经系统抑制综合征。神经声像图检查显示了,实质弥漫性缺血性病变、矢状旁和脑室周围多灶性病变的回声征象。

第七天进行了**磁共振成像**(MRI)检查。结果显示了,大脑大半球的脑浆子广泛出现小灶性病变,传导通路(胼胝体和皮质脊髓束)继发受累。这些变化被认为是色素失禁症(布洛赫-苏兹伯格综合征)框架内多发性脑梗塞的后果。

## 讨论

布洛赫-苏兹伯格综合症的基因缺陷导致细胞(胚胎外胚层的衍生物)在暴露于细胞因子时更容易凋亡[13]。这些组织包括皮肤及其衍生物(指甲、头发、牙齿)以及神经系统。该病通常在婴儿出生后的头十天发病。但婴儿出生后也可能出现任何阶段的病症:在这种情况下,可以认为前几个阶段是在宫内发生的。

患者L在出生后的第一天发病。疾病的表现很典型:出现线状皮疹并伴有神经症状。随着时间的推移,皮疹出现了特征性的病理形态变化。病理形态与疾病的分期相对应。

大脑磁共振成像显示出多个弥散受限的小病灶(最小尺寸为2mm)。这些病灶杂乱无章地分布在深部白质、皮层和皮层下、胼胝体、内囊后部、大脑脚以及皮质脊髓和其他束的沿线(图2)。传导通路的变化可被视为色素失禁症的直接病变或早期

瓦勒氏(前瓦勒氏)变性的表现。后者是由于轴突死亡和髓鞘解体导致的传导通路损伤[14]。我们将扩散受限的小病灶视为组织坏死(梗塞)。

文献描述了与中小口径血管壁损伤有关的小局灶性脑梗塞的发病机制。这导致了微出血和血栓形成。也有描述双侧大面积出血性坏死并伴有脑组织普遍破坏的病例[15]。

在我们的病例中,大脑磁共振成像显示了,在众多病灶中,只有少数病灶有出血转化的因素。它们与缺血区域相对应(图3, a)。这说明并非所有缺血灶都伴有出血。坏死区会进一步转化为脑缺血区,但部分受影响较小的区域在磁共振成像上几乎可以完全恢复到正常的脑物质结构[16]。在大脑皮层区域以及额叶和顶叶的白质和灰质交界处发现了T1加权图像上信号增强的区域(见图3, b)。这些区域与皮质坏死相似。它发生在大脑皮层缺血性损伤期间,导致单核细胞浸润和细胞碎片、受损结构的吞噬细胞作用。T1信号增加是由于死亡细胞和/或含有脂质的巨噬细胞的变性蛋白质沉积所致[17]。

此外,文献[18]还描述了一些经组织学证实的病例,色素失禁症患者的软网和大脑出现炎症性病变,并伴有细胞(嗜酸性粒细胞)浸润,类似于感染性病变,但无明显的血管异常。

根据磁共振成像数据进行的鉴别诊断主要是在脑炎和围产期缺血缺氧性病变的情况下进行的。脑炎的特点是以皮质病变为主,在T2-WI上呈稀疏扩展的磁共振信号增强区,弥散可能受限或增强。与此同时,色素失禁症会出现杂乱无章的小灶性病变。它在白质中的定位程度更高。围产期缺血的表现形式与大脑结构的成熟度有关。早产儿的特征是脑室周围白斑、基底节病变或与动脉基底相应的梗死。栓塞性脑梗塞的鉴别诊断比较困难,需要结合病史和对患者的检查进行综合分析。

水泡期皮疹和神经系统表现可能被误认为是疱疹病毒感染。在这种情况下,结合磁共振成

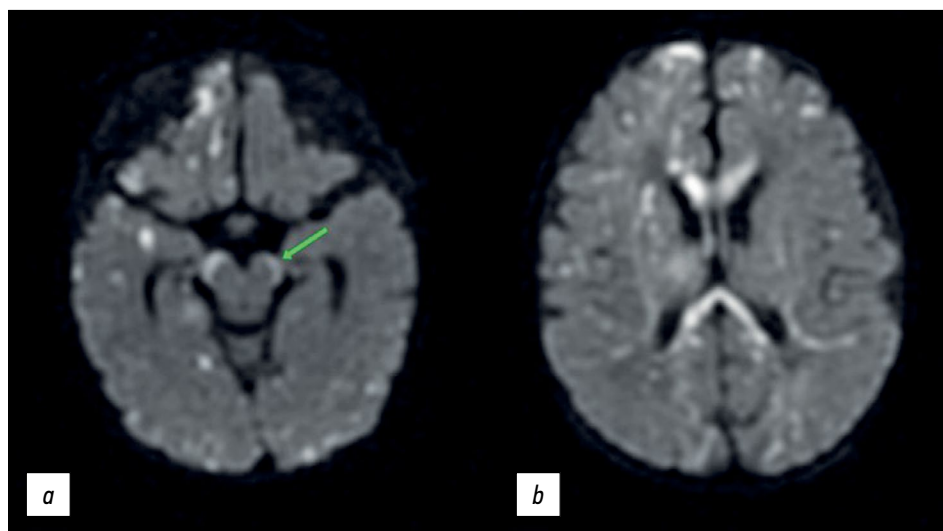
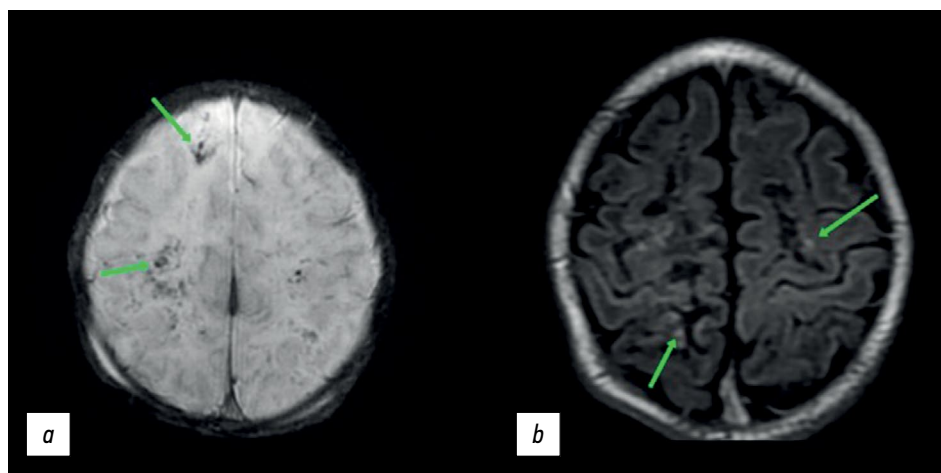


图2. 大脑弥散加权图像, 轴向面: a——箭头指大脑脚的传导通路信号增加; b——胼胝体的多发病灶和病变。



**图3.** 大脑磁共振成像：*a*——SWI图像（磁敏感加权成像）（箭头指微出血灶）；*b*——T1加权图像（箭头指皮质坏死的高密度区）。

像结果、具有分期病理形态的特征性皮炎以及疱疹病毒感染的阴性检测结果，极有可能是色素失禁症。

## 结论

由于皮炎的特殊性及其分期，诊断色素失禁症的关键在于皮肤科医生。IKBKG基因的分子遗传学检测方法在确诊中起着重要作用。

布洛赫-苏兹伯格综合征患者的大脑磁共振成像是出现神经症状时评估脑浆子病变严重程度的优先方法。该方法可安全地进行动态观察。它可以客观评估康复潜力、纠正适应训练措施并预测儿童的发展。

## ADDITIONAL INFORMATION

**Funding source.** This article was not supported by any external sources of funding.

## СПИСОК ЛИТЕРАТУРЫ

1. Scheuerle A.E., Ursini M.V., Adam M.P., et al. Incontinentia pigmenti. In: GeneReviews [Internet], Seattle (WA): University of Washington, Seattle, 1993.
2. Fusco F. Molecular analysis of the genetic defect in a large cohort of IP patients and identification of novel NEMO mutations interfering with NF- $\kappa$ B activation // *Hum Mol Genet.* 2004. Vol. 13, N 16. P. 1763–1773. doi: 10.1093/hmg/ddh192
3. Yadlapati S., Tripathy K. Incontinentia pigmenti (Bloch Sulzberger Syndrome). In: StatPearls [Internet]. Treasure Island (FL): StatPearls Publishing, 2023.
4. Савостьянов К.В. Современные алгоритмы генетической диагностики редких наследственных болезней у российских пациентов. Москва: Полиграфист и издатель, 2022. 451 с.
5. Minić S., Cerovac N., Novaković I., et al. The impact of the IKBKG gene on the appearance of the corpus callosum abnormalities in incontinentia pigmenti // *Diagnostics.* 2023. Vol. 13, N 7. P. 1300. doi: 10.3390/diagnostics13071300
6. Chistiakov D.A., Savostanov K.V., Kuzenkova L.M., et al. Molecular characteristics of patients with glycosaminoglycan storage disorders in Russia // *Clin Chim Acta.* 2014. N 436. P. 112–120. doi: 10.1016/j.cca.2014.05.010
7. Chistyakov D.A., Savostanov K.V., Nosikov V.V., Turakulov R.I. Genetic determinants of Graves' disease // *Mol Gen Metabol.* 2000. Vol. 71, N 1-2. P. 66–69. doi: 10.1006/mgme.2000.3042
8. Meuwissen M.E., Mancini G.M. Neurological findings in incontinentia pigmenti: A review // *Eur J Med Genet.* 2012. Vol. 55, N 5. P. 323–331. doi: 10.1016/j.ejmg.2012.04.007

**Competing interests.** The authors declare that they have no competing interests.

**Authors' contribution.** All authors made a substantial contribution to the conception of the work, acquisition, analysis, interpretation of data for the work, drafting and revising the work, final approval of the version to be published and agree to be accountable for all aspects of the work. I.I. Yarmola — writing text of the article, planning article structure, imaging analysis; A.V. Anikin — editing of the article, analytical work, discussion of the results, read and approved the direction of the manuscript for publication; D.A. Gankin — editing the text of the article, discussion of the results; L.E. Fomina — edition of the text of the article; N.A. Kharitonova — read and approved the direction of the manuscript for publication; I.S. Zhanin, A.A. Pushkov — article editing, conducting molecular genetic analysis; O.B. Kondakova — article editing, genetic counseling of the patient.

**Consent for publication.** Written consent was obtained from the patient's parents for publication of relevant medical information and all of accompanying images within the manuscript in Digital Diagnostics journal.

9. Carney R.G. Incontinentia pigmenti. A world statistical analysis // *Arch Dermatol*. 1976. Vol. 112, N 4. P. 535–542.
10. Minić S., Trpinac D., Obradović M. Incontinentia pigmenti diagnostic criteria update // *Clin Genet*. 2014. Vol. 85, N 6. P. 536–542. doi: 10.1111/cge.12223
11. Haque M.N., Ohtsubo M., Nishina S., et al. Analysis of IKBKG/NEMO gene in five Japanese cases of incontinentia pigmenti with retinopathy: Fine genomic assay of a rare male case with mosaicism // *J Hum Genet*. 2021. Vol. 66, N 2. P. 645–645. doi: 10.1038/s10038-020-00836-3
12. Kawai M., Kato T., Tsutsumi M., et al. Molecular analysis of low-level mosaicism of the IKBKG mutation using the X Chromosome Inactivation pattern in Incontinentia Pigmenti // *Mol Genet Genomic Med*. 2020. Vol. 8, N 12. P. e1531. doi: 10.1002/mgg3.1531
13. Tak P.P., Firestein G.S. NF- $\kappa$ B: A key role in inflammatory diseases // *J Clin Invest*. 2001. Vol. 107, N 1. P. 7–11. doi: 10.1172/JCI11830
14. Kleinman J.T. Early Wallerian degeneration on magnetic resonance imaging: Underappreciated but highly relevant // *Dev Med Child Neurol*. 2013. Vol. 55, N 2. P. 104–105. doi: 10.1111/dmcn.12022
15. Salamon S.A., Lichtenbelt K., Cowan F.M., et al. Clinical presentation and spectrum of neuroimaging findings in newborn infants with incontinentia pigmenti // *Dev Med Child Neurol*. 2016. Vol. 58, N 10. P. 1076–1084. doi: 10.1111/dmcn.13140
16. Lou H., Zhang L., Xiao W., et al. Nearly completely reversible brain abnormalities in a patient with incontinentia pigmenti // *Am J Neuroradiol*. 2008. Vol. 29, N 3. P. 431–433. doi: 10.3174/ajnr.A0890
17. Kinoshita T., Ogawa T., Yoshida Y., et al. Curvilinear T1 hyperintense lesions representing cortical necrosis after cerebral infarction // *Neuroradiology*. 2005. Vol. 47, N 7. P. 647–651. doi: 10.1007/s00234-005-1398-0
18. Hauw J.J., Perié G., Bonnette J., Escourolle R. [Neuropathological study of incontinentia pigmenti. Anatomical case report (author's transl). (In French)] // *Acta Neuropathol*. 1977. Vol. 38, N 2. P. 159–162. doi: 10.1007/BF00688564

## REFERENCES

1. Scheuerle AE, Ursini MV, Adam MP, et al. Incontinentia Pigmenti. In: GeneReviews [Internet], Seattle (WA): University of Washington, Seattle; 1993.
2. Fusco F. Molecular analysis of the genetic defect in a large cohort of IP patients and identification of novel NEMO mutations interfering with NF- $\kappa$ B activation. *Hum Mol Genet*. 2004;13(16):1763–1773. doi: 10.1093/hmg/ddh192
3. Yadlapati S, Tripathy K. Incontinentia pigmenti (Bloch Sulzberger Syndrome). In: StatPearls [Internet]. Treasure Island (FL): StatPearls Publishing; 2023.
4. Savostyanov KV. Modern algorithms of genetic diagnosis of rare hereditary diseases in Russian patients. Moscow: Polygraphist Publisher; 2022. 451 p. (In Russ).
5. Minić S, Cerovac N, Novaković I, et al. The impact of the IKBKG gene on the appearance of the corpus callosum abnormalities in incontinentia pigmenti. *Diagnostics*. 2023;13(7):1300. doi: 10.3390/diagnostics13071300
6. Chistiakov DA, Savostanov KV, Kuzenkova LM, et al. Molecular characteristics of patients with glycosaminoglycan storage disorders in Russia. *Clin Chim Acta*. 2014;(436):112–120. doi: 10.1016/j.cca.2014.05.010
7. Chistyakov DA, Savostanov KV, Nosikov VV, Turakulov RI. Genetic determinants of Graves' disease. *Mol Gen Metabol*. 2000;71(1-2):66–69. doi: 10.1006/mgme.2000.3042
8. Meuwissen ME, Mancini GM. Neurological findings in incontinentia pigmenti: A review. *Eur J Med Genet*. 2012;55(5):323–331. doi: 10.1016/j.ejmg.2012.04.007
9. Carney RG. Incontinentia pigmenti. A world statistical analysis. *Arch Dermatol*. 1976;112(4):535–542.
10. Minić S, Trpinac D, Obradović M. Incontinentia pigmenti diagnostic criteria update. *Clin Genet*. 2014;85(6):536–542. doi: 10.1111/cge.12223
11. Haque MN, Ohtsubo M, Nishina S, et al. Analysis of IKBKG/NEMO gene in five Japanese cases of incontinentia pigmenti with retinopathy: Fine genomic assay of a rare male case with mosaicism. *J Hum Genet*. 2021;66(2):645–645. doi: 10.1038/s10038-020-00836-3
12. Kawai M, Kato T, Tsutsumi M, et al. Molecular analysis of low-level mosaicism of the IKBKG mutation using the X Chromosome Inactivation pattern in Incontinentia Pigmenti. *Mol Genet Genomic Med*. 2020;8(12):e1531. doi: 10.1002/mgg3.1531
13. Tak PP, Firestein GS. NF- $\kappa$ B: A key role in inflammatory diseases. *J Clin Invest*. 2001;107(1):7–11. doi: 10.1172/JCI11830
14. Kleinman JT. Early Wallerian degeneration on magnetic resonance imaging: Underappreciated but highly relevant. *Dev Med Child Neurol*. 2013;55(2):104–105. doi: 10.1111/dmcn.12022
15. Salamon SA, Lichtenbelt K, Cowan FM, et al. Clinical presentation and spectrum of neuroimaging findings in newborn infants with incontinentia pigmenti. *Dev Med Child Neurol*. 2016;58(10):1076–1084. doi: 10.1111/dmcn.13140
16. Lou H, Zhang L, Xiao W, et al. Nearly completely reversible brain abnormalities in a patient with incontinentia pigmenti. *Am J Neuroradiol*. 2008;29(3):431–433. doi: 10.3174/ajnr.A0890
17. Kinoshita T, Ogawa T, Yoshida Y, et al. Curvilinear T1 hyperintense lesions representing cortical necrosis after cerebral infarction. *Neuroradiology*. 2005;47(7):647–651. doi: 10.1007/s00234-005-1398-0
18. Hauw JJ, Perié G, Bonnette J, Escourolle R. [Neuropathological study of incontinentia pigmenti. Anatomical case report (author's transl). (In French)]. *Acta Neuropathol*. 1977;38(2):159–162. doi: 10.1007/BF00688564

## AUTHORS' INFO

**\* Igor I. Yarmola;**

address: 2/1 Lomonosovsky prospekt, 119991  
Moscow, Russia;  
ORCID: 0000-0002-1272-5119;  
eLibrary SPIN: 5591-8066;  
e-mail: Lord\_Dukich@bk.ru

**Anatoly V. Anikin, MD, Cand. Sci. (Med.);**

ORCID: 0000-0003-0362-6511;  
eLibrary SPIN: 7592-1352;  
e-mail: anikacor@gmail.com

**Dmitry A. Gankin;**

ORCID: 0009-0001-6779-8702;  
e-mail: ganja-nn@yandex.ru

**Lyubov E. Fomina;**

ORCID: 0000-0002-3838-3284;  
eLibrary SPIN: 1298-8350;  
e-mail: love.fomina@mail.ru

**Nataliya A. Kharitonova, MD, Cand. Sci. (Med.);**

ORCID: 0000-0002-6912-1471;  
eLibrary SPIN: 7379-8269;  
e-mail: Kharitonova.na@nczd.ru

**Ilya S. Zhanin, MD, Cand. Sci. (Med.);**

ORCID: 0000-0003-1423-0379;  
eLibrary SPIN: 6108-2016;  
e-mail: zhanin.is@nczd.ru

**Alexander A. Pushkov, Cand. Sci. (Biol.);**

ORCID: 0000-0001-6648-2063;  
eLibrary SPIN: 2928-5764;  
e-mail: pushkov.aa@nczd.ru

**Milana A. Basargina, MD, Cand. Sci. (Med.);**

ORCID: 0000-0003-2075-6668;  
eLibrary SPIN: 5504-7154;  
e-mail: basargina.ma@nczd.ru

**Olga B. Kondakova, MD, Cand. Sci. (Med.);**

ORCID: 0000-0002-6316-9992;  
eLibrary SPIN: 9066-3698;  
e-mail: kondakova.ob@nczd.ru

## ОБ АВТОРАХ

**\* Ярмола Игорь Игоревич;**

адрес: Россия, 119991, Москва, Ломоносовский проспект,  
д. 2, стр. 1;  
ORCID: 0000-0002-1272-5119;  
eLibrary SPIN: 5591-8066;  
e-mail: Lord\_Dukich@bk.ru

**Аникин Анатолий Владимирович, канд. мед. наук;**

ORCID: 0000-0003-0362-6511;  
eLibrary SPIN: 7592-1352;  
e-mail: anikacor@gmail.com

**Ганькин Дмитрий Александрович;**

ORCID: 0009-0001-6779-8702;  
e-mail: ganja-nn@yandex.ru

**Фомина Любовь Евгеньевна;**

ORCID: 0000-0002-3838-3284;  
eLibrary SPIN: 1298-8350;  
e-mail: love.fomina@mail.ru

**Харитонова Наталья Александровна, канд. мед. наук;**

ORCID: 0000-0002-6912-1471;  
eLibrary SPIN: 7379-8269;  
e-mail: Kharitonova.na@nczd.ru

**Жанин Илья Сергеевич, канд. мед. наук.;**

ORCID: 0000-0003-1423-0379;  
eLibrary SPIN: 6108-2016;  
e-mail: zhanin.is@nczd.ru

**Пушков Александр Алексеевич, канд. биол. наук;**

ORCID: 0000-0001-6648-2063;  
eLibrary SPIN: 2928-5764;  
e-mail: pushkov.aa@nczd.ru

**Басаргина Милана Александровна, канд. мед. наук;**

ORCID: 0000-0003-2075-6668;  
eLibrary SPIN: 5504-7154;  
e-mail: basargina.ma@nczd.ru

**Кондакова Ольга Борисовна, канд. мед. наук;**

ORCID: 0000-0002-6316-9992;  
eLibrary SPIN: 9066-3698;  
e-mail: kondakova.ob@nczd.ru

\* Corresponding author / Автор, ответственный за переписку