

DOI: <https://doi.org/10.17816/DD90277>

Разрыв яичка у молодого пациента: диагностическая ценность ультразвукового исследования с контрастным усилением

L. Eusebi¹, M.T. Paparella², A. Marconi³, G. Guglielmi^{2, 4}¹ Radiology Unit, "Carlo Urbani" Hospital, Джези, Италия² Department of Clinical and Experimental Medicine, Foggia University School of Medicine, Фоджа, Италия³ Department of Urology, "Carlo Urbani" Hospital, Джези, Италия⁴ Radiology Unit, Barletta University Campus UNIFG, "Dimiccoli" Hospital, Фоджа, Италия

АННОТАЦИЯ

Разрыв яичка, возникший в результате тупой травмы мошонки, характеризуется повреждением белочной оболочки, что приводит к экстррузии семенных канальцев.

Методы визуализации, в частности ультразвуковое исследование, играют важнейшую роль в оценке травмы мошонки и позволяют определить дальнейшую тактику ведения пациента — консервативное лечение или хирургическое вмешательство. Ультразвуковое исследование в стандартном В-режиме и цветное доплеровское картирование являются основными методами визуализации при оценке травмы яичка, однако малоинформативны в отношении степени его повреждения. Наиболее важной информацией для хирурга являются целостность или разрыв белочной оболочки и степень повреждения жизненно важных тканей яичка. О последнем сложно судить, исходя лишь из данных стандартной ультрасонографии, по причине гиперваскуляризации яичка, возникающей вследствие отёка, нарушающего сосудистый кровоток. В случае сомнительных результатов цветного доплеровского картирования необходимо прибегать к другим современным методам визуализации, в частности к ультразвуковому исследованию с контрастным усилением, позволяющим определять жизнеспособность травмированного яичка.

В данной статье описывается клинический случай тупой травмы яичка у 15-летнего футболиста.

Ключевые слова: разрыв яичка; травма мошонки; цветовая доплеровская ультрасонография; ультразвуковое исследование с контрастным усилением; клинический случай.

Как цитировать

Eusebi L., Paparella M.T., Marconi A., Guglielmi G. Разрыв яичка у молодого пациента: диагностическая ценность ультразвукового исследования с контрастным усилением // *Digital Diagnostics*. 2022. Т. 3, № 1. С. 78–85. DOI: <https://doi.org/10.17816/DD90277>

DOI: <https://doi.org/10.17816/DD90277>

Testicular rupture in a young patient: diagnostic value of contrast-enhanced ultrasonography

Laura Eusebi¹, Maria T. Paparella², Andrea Marconi³, Giuseppe Guglielmi^{2, 4}

¹ Radiology Unit, "Carlo Urbani" Hospital, Jesi, Italy

² Department of Clinical and Experimental Medicine, Foggia University School of Medicine, Foggia, Italy

³ Department of Urology, "Carlo Urbani" Hospital, Jesi, Italy

⁴ Radiology Unit, Barletta University Campus UNIFG, "Dimiccoli" Hospital, Foggia, Italy

ABSTRACT

Testicular rupture after a blunt scrotal trauma is characterized by tearing of the tunica albuginea that result in the extrusion of the seminiferous tubules.

Imaging, particularly ultrasonography, plays a crucial role in the assessment of scrotal trauma and directs patient management toward conservative or surgical treatment. Conventional B-mode and color Doppler ultrasonography are the main imaging techniques in the evaluation of the testicle in trauma but may underestimate the extent of injury. The most important information for the surgeon is the integrity or interruption of the tunica albuginea and the extent of vital testicular tissue. The latter is often difficult to assess with conventional ultrasonography because the injured testicle is often hypovascular even in vital regions due to testicular edema that compromises vascular flow. The selective use of advanced techniques such as contrast-enhanced ultrasonography is important in identifying testicular viability when color Doppler ultrasonography is equivocal.

This case report describes the evaluation and management of a blunt testicular trauma in a 15-year-old football player.

Keywords: testicular rupture; scrotal trauma; color Doppler ultrasound; contrast-enhanced ultrasound; clinical case.

To cite this article

Eusebi L, Paparella MT, Marconi A, Guglielmi G. Testicular rupture in a young patient: diagnostic value of contrast-enhanced ultrasonography. *Digital Diagnostics*. 2022;3(1):78–85. DOI: <https://doi.org/10.17816/DD90277>

Received: 13.12.2021

Accepted: 02.03.2022

Published: 30.03.2022

DOI: <https://doi.org/10.17816/DD90277>

年轻患者睾丸破裂以及对比增强超声检查的诊断价值

Laura Eusebi¹, Maria T. Paparella², Andrea Marconi³, Giuseppe Guglielmi^{2,4}

¹ Radiology Unit, "Carlo Urbani" Hospital, Jesi, Italy

² Department of Clinical and Experimental Medicine, Foggia University School of Medicine, Foggia, Italy

³ Department of Urology, "Carlo Urbani" Hospital, Jesi, Italy

⁴ Radiology Unit, Barletta University Campus UNIFG, "Dimiccoli" Hospital, Foggia, Italy

简评

由于阴囊钝性伤发生的睾丸破裂的特点是鞘膜受损，导致细精管挤压。

显现法，尤其是超声，在评估阴囊损伤方面发挥着至关重要的作用，并允许确定患者管理的进一步策略——保守治疗或外科手术。标准B模式超声和彩超是评估睾丸损伤的主要显现法，但对睾丸损伤的程度意义不大。外科医生最重要的信息是鞘膜的完整性或破裂以及睾丸重要组织的损伤程度。由于水肿破坏了血管血流，导致睾丸的血管形成过多，仅从标准的超声检查的数据很难判断后者。如果彩色多普勒绘图的结果不确定，则必须使用其他现代成像方式，如造影剂增强超声，以确定受伤睾丸的生存能力。

本文描述了一名15岁足球运动员睾丸钝性伤的临床病例。

关键词： 睾丸破裂； 阴囊损伤； 彩色多普勒超声检查； 对比增强超声； 病例。

To cite this article

Eusebi L, Paparella MT, Marconi A, Guglielmi G. 年轻患者睾丸破裂以及对比增强超声检查的诊断价值. *Digital Diagnostics*. 2022;3(1):78-85.

DOI: <https://doi.org/10.17816/DD90277>

收到: 13.12.2021

接受: 02.03.2022

发布日期: 30.03.2022

BACKGROUND

Scrotal trauma in young men accounts for less than 1% of all trauma-related injuries [1]. Testicular ruptures are seen in approximately 1.5% of cases of blunt scrotal trauma [2]. Less than 60 cases have been reported over the past decade [3]. The testicles are protected in their mobility within the scrotum by the tunica albuginea, laxity of the overlying skin, and contraction reflex of the cremasteric muscles. The tunica albuginea, with its great tensile strength, plays a crucial role in protecting the testicle; it can withstand a force of up to 50 kg without breaking [2]. The laxity of the genital skin can protect the underlying organs from blunt trauma allowing them to slip away from the point of contact; nevertheless, excessive skin laxity can lead to serious injury if the genital skin remains trapped in rotating machinery, causing avulsion and rupture of one or both testicles [4]. Sports activities account for more than 50% of all cases of testicular injuries, and motor vehicle collisions is another cause of scrotal trauma [5, 6]. Blunt injuries are noninvasive injuries due to the high energy transferred during contact with a solid object (e.g., from a kick in the groin or from the impact of a baseball or hockey bat). The main injury mechanism is the crushing of the testicle against the pubic symphysis or between the thighs. In most men, the right testicle is injured more frequently because it has an anatomical position slightly higher than that of the left testicle [7]. Scrotal trauma causes hemorrhage and infarction of the testicular parenchyma, which could lead to necrosis. In severe injuries, the disruption of the tunica albuginea accompanied by parenchymal protrusion can occur. It represents an indication for urgent surgery to salvage the testis [8]. Moreover, early repair is crucial, as rupture can damage the blood–testis barrier, with subsequent antibody formation against sperm cells leading to infertility [9]. This

case study describes the evaluation and management of a blunt testicular trauma in a 15-year-old football player.

DESCRIPTION OF THE CASE

A healthy 15-year-old male teen was hit in the scrotum with a kick in the groin during a football match. He had an immediate and severe pain. After a few hours, although symptoms had improved, he presented to our emergency department with persistent swelling and purplish discoloration of the left scrotum. He did not report any other injuries. The genitourinary examination revealed that the left hemiscrotum was about two times larger than the right with severe ecchymosis. The left testicle was difficult to palpate because of pain and swelling, whereas the right testicle had a normal size and did not reveal any palpable abnormalities. The cremasteric reflex was not elicited on the left side. Scrotal ultrasonography (US) showed moderate scrotal edema and hematocele with a discontinuity in the tunica albuginea characterized by an abnormal contour (Figure 1). Color Doppler US (CDUS) documented a loss of vascularization in the upper pole that extruded into the broken portion of the testicle of approximately 2.5 cm (Figure 2) but no evidence of torsion or infarction. Urology consultation was requested, and a contrast-enhanced US (CEUS) was performed, which confirmed the diagnosis of testicular rupture and determined the amount of the vital parenchyma (Figure 3). The patient was hospitalized for urgent examination of the left hemiscrotum based on the US results. During surgery, a large hematocele was evacuated, and a closer inspection of the testicle revealed a lesion of the tunica albuginea. Primary closure of the tunica was performed (Figure 4). The patient made an uneventful recovery, and he was discharged after 4 days.

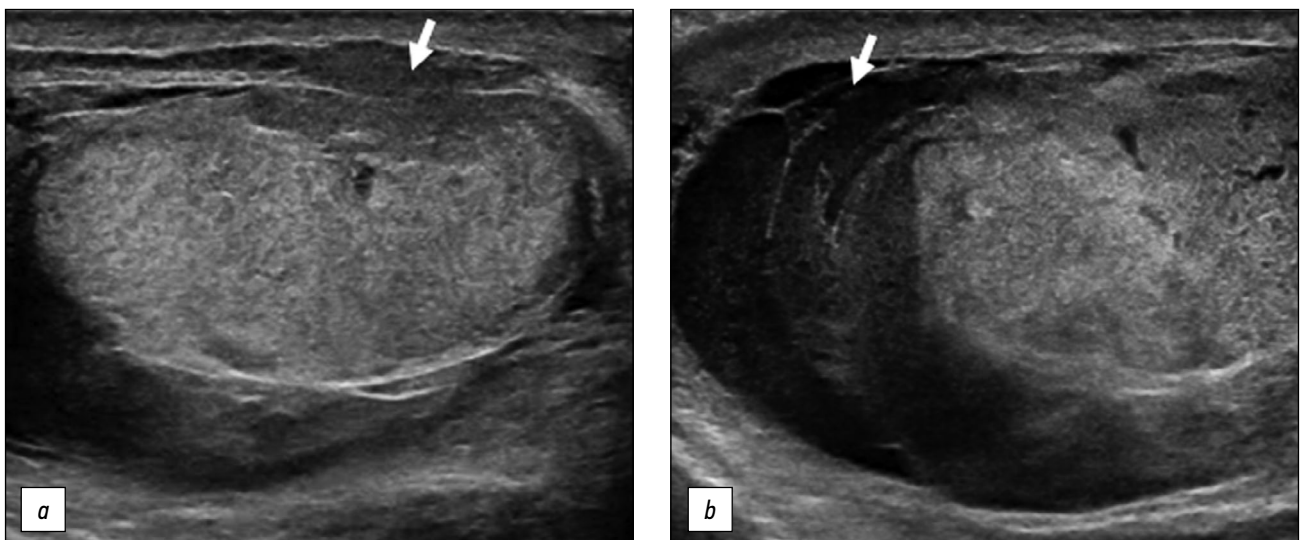


Figure 1. B-mode ultrasonography images. (a) Interruption of the tunica albuginea with the protrusion of echogenic material (arrow) that represents an index of breaking. (b) Hematocele of moderate size (arrow) and a heterogeneous appearance of testicular parenchyma, attributable to an intratesticular contusion.

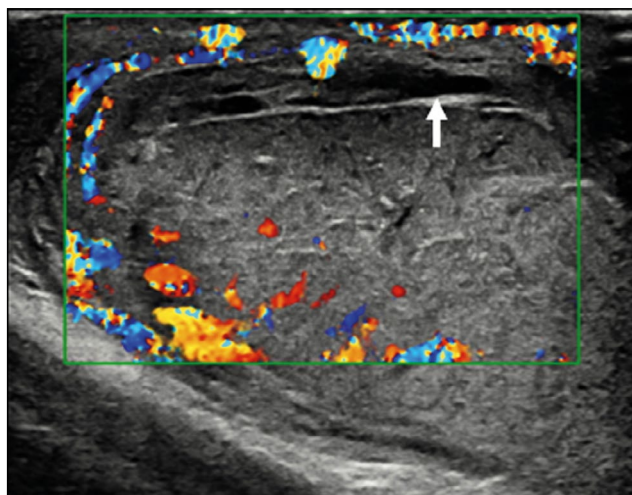


Figure 2. Color Doppler ultrasonography image showing an irregular testicular morphology with an avascular area at the breaking point (arrow).

DISCUSSION

The differential diagnosis of scrotal lesions includes epididymitis, orchitis, incarcerated inguinal hernia, testicular infarction, testicular fracture or rupture, testicular torsion, appendicular torsion, dislocated testicles, hydrocele, or hematocele [10]. CDUS is the first-line imaging modality for studying traumatic pathology of the scrotum according to the guidelines of the European Association of Urology [11]. Thus, evaluating vascular perfusion and testicular integrity is important to distinguish testicular rupture from other lesions. Using modern ultrasonic equipment, sensitivity and specificity of 95%–100% are now possible

for the diagnosis of testicular rupture [12]. The normal tunica albuginea appears as a thin hypoechoic line surrounding the testicular parenchyma. It can be difficult to appreciate it in the presence of hematocele. The regularity of the testicular contour should be checked in addition to the integrity of the tunica albuginea. Essentially, when testicular rupture occurs, the testicle loses its normal oval morphology because of parenchymal extrusion [13]. Thus, the irregularity of the testicle's morphology is an indirect sign of ruptured tunica albuginea. Additional US findings include heterogeneous echotexture, rupture of the vaginal tunic, fracture lines through the testicle, decrease or loss of blood flow, scrotal thickening, and hematocele formation. CDUS is indispensable in the evaluation of a post-traumatic scrotum [14] since the rupture of the tunica albuginea is always associated with a rupture of the tunica vasculosa (composed of capsular arteries), resulting in a loss of the vascular signal of the underlying parenchyma. This aspect is extremely important because it can help determine the viability of the testicular parenchyma [15]. However, CDUS can be equivocal in acute cases because it may not detect low-flow states, particularly in pediatric patients [16], and is considered unreliable in defining ischemia [17] that could cause a delay in appropriate surgical treatment. CEUS can be proposed in cases where conventional US diagnosis remains inconclusive. CEUS is very sensitive to reveal the parenchymal vascularity and its changes in the damaged testicle [18]. The official guidelines of the European Federation of Societies for Ultrasound in Medicine and Biology describe the usefulness of CEUS in many areas [19]. Usually, 4.8 mL of SonoVue™ (Bracco Spa, Milan) is used.

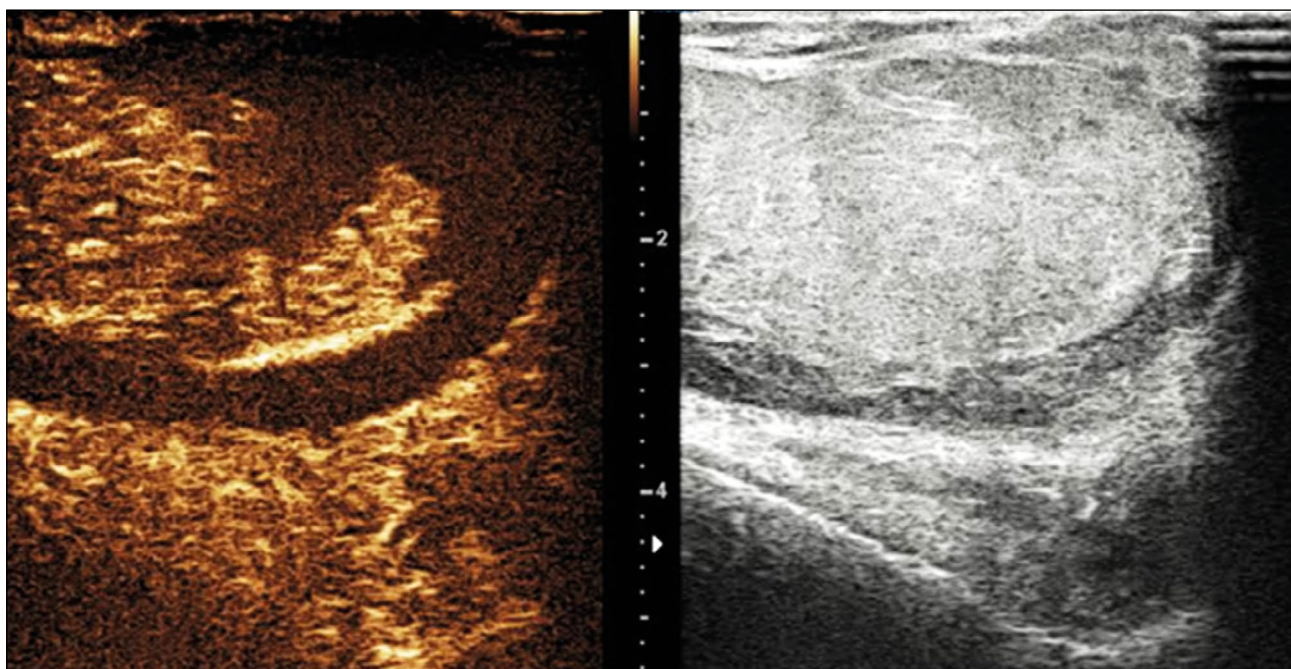


Figure 3. Contrast-enhanced ultrasonography image determines the extent of vital parenchyma, helping in the preoperative decision-making process, and allows the recovery of vital testicular tissue, avoiding the need for orchidectomy.

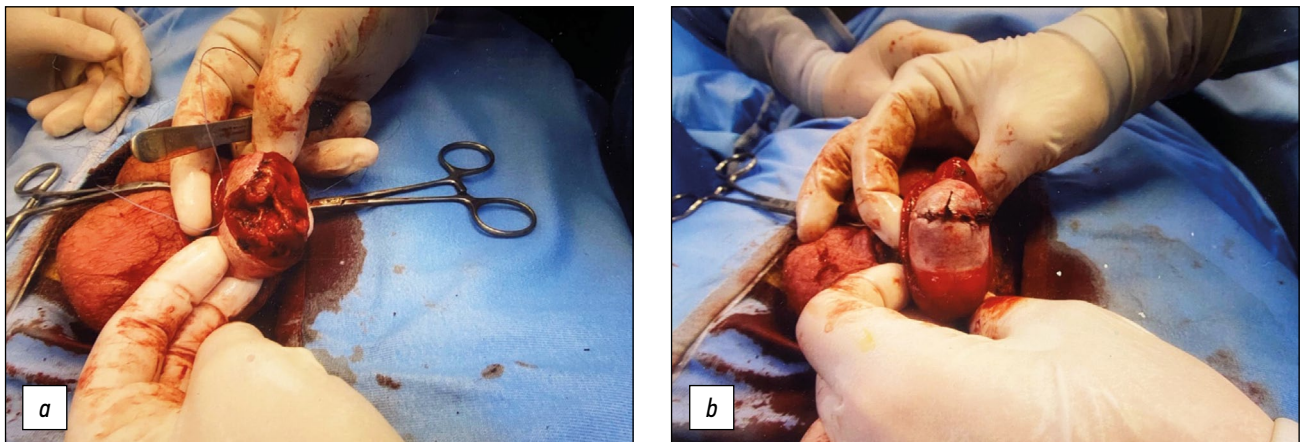


Figure 4. Intraoperative images. (a) Confirmed rupture of the tunica albuginea. (b) Primary albuginea closure.

Contrast agents for CEUS examination are not nephrotoxic, the phospholipidic shell is metabolized by the liver, and the sulfur hexafluoride gaseous component is exhaled through the lungs. The technique can be performed in patients with kidney failure and does not require previous laboratory tests. In addition, ultrasonic contrast agents (UCAs) have a lower risk of adverse reactions than contrast agents commonly used in computed tomography and magnetic resonance imaging. The CEUS is also inexpensive, fast, portable, repeatable, and safe with multiple injections, all without radiation exposure [20]. The arterial phase in CEUS is the most important tool of the examination. The testicle and epididymis enhance quickly, but it can vary from individual to individual. Arteries enhance first, followed in seconds by the reinforcement of the entire parenchyma. The scrotal wall tends to enhance lesser than the content. The enhancement decreases in a variable period usually 3 min. The normal testicular parenchyma is homogeneous with an echogenic surface line indicating the tunica albuginea. On CEUS, the testicle should enhance homogeneously with a striated pattern representing UCAs within the normal intratesticular vascular anatomy [20]. CEUS more clearly depicts the fracture lines, interruption of the tunica albuginea, and both intratesticular and extratesticular hematomas [21]. It can assess exact extent of viable testis, allowing the urologist to decide when the partial salvage of the organ is a good solution [22]. In addition, small testicular tumors may appear avascular in CDUS; thus, the differentiation of infarction can be difficult. CEUS can distinguish vascularized from non-vascularized focal testicular lesions, which help exclude malignancy. Finally, the Scrotal and Penile Imaging Working Group of the European Society of Urogenital Radiology provided position statements with the aim of guiding the use of imaging, especially multiparametric US, in scrotal trauma. Accordingly, CEUS can be used to identify the presence or absence of flow when CDUS is not diagnostic; identify testicular ruptures, fracture lines, hematomas, and ischemic changes in equivocal cases in conventional US; and distinguish between avascular and

poorly vascularized lesions, to differentiate hematomas from tumors [23].

CONCLUSION

Scrotal US is the first-line imaging modality for the diagnosis of testicular trauma. Currently, CEUS is the first-line imaging modality for studying the traumatic pathology of the scrotum. CEUS has the potential to become an indispensable tool in the assessment of acute scrotal trauma, providing accurate and diagnostic imaging and helping increase the confidence of the doctor. The use of contrast media in US may be an optimal solution for a prompt resolution of equivocal US findings, combining the facility of US and information on the parenchymal vascularity offered by CEUS. This is particularly relevant for the surgical decision as to whether or not to undertake emergency surgery and, above all, whether the affected testicle is salvageable. The current management strategy for testicular rupture is surgical exploration and repair within 72 h to maximize the rescue.

ADDITIONAL INFORMATION

Funding source. This study was not supported by any external sources of funding.

Competing interest. Authors declare no explicit and potential conflicts of interests associated with the publication of this article.

Authors' contribution. All authors made a substantial contribution to the conception of the work; acquisition, analysis, and interpretation of data for the work; drafting and revising the work; final approval of the version to be published; and agree to be accountable for all aspects of the work. L. Eusebi and M.T. Paparella contributed equally to the research work related to the topic and manuscript writing; A. Marconi helped in literature research and data acquisition; G. Guglielmi was involved in the critical revision of the manuscript.

Consent for publication. Written consent was obtained from the patient for the publication of relevant medical information and all accompanying images.

REFERENCES

1. Deurdulian C, Mittelstaedt CA, Chong WK, Fielding JR. US of acute scrotal trauma: optimal technique, imaging findings, and management. *Radiographics*. 2007;27(2):357–369. doi: 10.1148/rg.272065117
2. Bhatt S, Dogra VS. Role of US in testicular and scrotal trauma. *Radiographics*. 2008;28(6):1617–1629. doi: 10.1148/rg.286085507
3. Sadjo SA, Destival C, Lemelle JL, Berte N. Testicular rupture after blunt scrotal trauma in children: a case report and literature review. *Trauma Case Rep*. 2021;33:100482. doi: 10.1016/j.tcr.2021.100482
4. Wessells H, Long L. Penile and genital injuries. *Urol Clin North Am*. 2006;33(1):117–126. doi: 10.1016/j.ucl.2005.11.003
5. Haas CA, Brown SL, Spirnak JP. Penile fracture and testicular rupture. *World J Urol*. 1999;17(2):101–106. doi: 10.1007/s003450050114
6. Munter DW, Faleski EJ. Blunt scrotal trauma: emergency department evaluation and management. *Am J Emerg Med*. 1989;7(2):227–234. doi: 10.1016/0735-6757(89)90143-5
7. Mulhall JP, Gabram SG, Jacobs LM. Emergency management of blunt testicular trauma. *Acad Emerg Med*. 1995;2(7):639–643. doi: 10.1111/j.1553-2712.1995.tb03604.x
8. Huang DY, Pesapane F, Rafailidis V, et al. The role of multiparametric ultrasound in the diagnosis of paediatric scrotal pathology. *Br J Radiol*. 2020;93(1110):20200063. doi: 10.1259/bjr.20200063
9. Wright S, Hoffmann B. Emergency ultrasound of acute scrotal pain. *Eur J Emerg Med*. 2015;22(1):2–9. doi: 10.1097/MEJ.0000000000000123
10. Wang A, Stormont I, Siddiqui MM. A review of imaging modalities used in the diagnosis and management of scrotal trauma. *Current Urology Reports*. 2017;18(12):98–103. doi: 10.1007/s11934-017-0744-1
11. Kitrey ND, Djakovic N, Gonsalves M, et al. EAU guidelines on urological trauma. European Association of Urology; 2016. Available from: <https://uroweb.org/individual-guidelines/non-oncology-guidelines/>
12. Cannis M, Mailhot T, Perera P. Bedside ultrasound in a case of blunt scrotal trauma. *West J Emergency Med*. 2013;14(2):127–129. doi: 10.5811/westjem.2012.8.12630
13. Bhatt S, Ghazale H, Dogra VS. Sonographic evaluation of scrotal and penile trauma. *Ultrasound Clin*. 2007;2(1):45–56. doi: 10.1016/j.cult.2007.01.003
14. Pepe P, Panella P, Pennisi M, Aragona F. Does color Doppler sonography improve the clinical assessment of patients with acute scrotum? *Eur J Radiol*. 2006;60(1):120–124. doi: 10.1016/j.ejrad.2006.04.016
15. Muttarak M, Thinyu S, Lojanapiwat B. Clinics in diagnostic imaging (114). Rupture of the right testis. *Singapore Med J*. 2007;48(3):264–268.
16. Yusuf G, Konstantatou E, Sellars ME, et al. Multiparametric sonography of testicular hematomas: features on grayscale, color Doppler, and contrast-enhanced sonography and strain elastography. *J Ultrasound Med*. 2015;34:1319–1328. doi: 10.7863/ultra.34.7.1319
17. Hedayati V, Sellars ME, Sharma DM, Sidhu PS. Contrast-enhanced ultrasound in testicular trauma: role in directing exploration, debridement and organ salvage. *Br J Radiol*. 2012;85(1011):e65–e68. doi: 10.1259/bjr/95600238
18. Badea R, Lucan C, Suciuc M, et al. Contrast enhanced harmonic ultrasonography for the evaluation of acute scrotal pathology. A pictorial essay. *Med Ultrason*. 2016;18(1):110–115. doi: 10.11152/mu.2013.2066.181.esy
19. Sidhu PS, Cantisani V, Dietrich CF, et al. The EFSUMB guidelines and recommendations for the clinical practice of contrast-enhanced ultrasound (CEUS) in non-hepatic applications: update 2017 (short version). *Ultraschall Med*. 2018;39(2):154–180. doi: 10.1055/s-0044-101254
20. Yusuf GT, Rafailidis V, Moore S, et al. The role of contrast-enhanced ultrasound (CEUS) in the evaluation of scrotal trauma: a review. *Insights Imaging*. 2020;11(1):68. doi: 10.1186/s13244-020-00874-7
21. Trinci M, Cirimele V, Ferrari R, et al. Diagnostic value of contrast-enhanced ultrasound (CEUS) and comparison with color Doppler ultrasound and magnetic resonance in a case of scrotal trauma. *J Ultrasound*. 2020;23(2):189–194. doi: 10.1007/s40477-019-00389-y
22. Valentino M, Bertolotto M, Derchi L, et al. Role of contrast enhanced ultrasound in acute scrotal diseases. *Eur Radiol*. 2011;21(9):1831–1840. doi: 10.1007/s00330-010-2039-5
23. Ramanathan S, Bertolotto M, Freeman S, et al. Imaging in scrotal trauma: a European Society of Urogenital Radiology Scrotal and Penile Imaging Working Group (ESUR-SPIWG) position statement. *Eur Radiol*. 2021;31(7):4918–4928. doi: 10.1007/s00330-020-07631-w

СПИСОК ЛИТЕРАТУРЫ

1. Deurdulian C., Mittelstaedt C.A., Chong W.K., Fielding J.R. US of acute scrotal trauma: optimal technique, imaging findings, and management // *Radiographics*. 2007. Vol. 27, N 2. P. 357–369. doi: 10.1148/rg.272065117
2. Bhatt S., Dogra V.S. Role of US in testicular and scrotal trauma // *Radiographics*. 2008. Vol. 28, N 6. P. 1617–1629. doi: 10.1148/rg.286085507
3. Sadjo S.A., Destival C., Lemelle J.L., Berte N. Testicular rupture after blunt scrotal trauma in children: A case report and literature review // *Trauma Case Rep*. 2021. Vol. 33. P. 100482. doi: 10.1016/j.tcr.2021.100482
4. Wessells H., Long L. Penile and genital injuries // *Urol Clin North Am*. 2006. Vol. 33, N 1. P. 117–126. doi: 10.1016/j.ucl.2005.11.003
5. Haas C.A., Brown S.L., Spirnak J.P. Penile fracture and testicular rupture // *World J Urol*. 1999. Vol. 17, N 2. P. 101–106. doi: 10.1007/s003450050114
6. Munter D.W., Faleski E.J. Blunt scrotal trauma: emergency department evaluation and management // *Am J Emerg Med*. 1989. Vol. 7, N 2. P. 227–234. doi: 10.1016/0735-6757(89)90143-5
7. Mulhall J.P., Gabram S.G., Jacobs L.M. Emergency management of blunt testicular trauma // *Acad Emerg Med*. 1995. Vol. 2, N 7. P. 639–643. doi: 10.1111/j.1553-2712.1995.tb03604.x
8. Huang D.Y., Pesapane F., Rafailidis V., et al. The role of multiparametric ultrasound in the diagnosis of paediatric scrotal pathology // *Br J Radiol*. 2020. Vol. 93, N 1110. P. 20200063. doi: 10.1259/bjr.20200063
9. Wright S., Hoffmann B. Emergency ultrasound of acute scrotal pain // *Eur J Emerg Med*. 2015. Vol. 22, N 1. P. 2–9. doi: 10.1097/MEJ.0000000000000123
10. Wang A., Stormont I., Siddiqui M.M. A review of imaging modalities used in the diagnosis and management of scrotal trauma // *Current Urology Reports*. 2017. Vol. 18, N 12. P. 98–103. doi: 10.1007/s11934-017-0744-1
11. Kitrey N.D., Djakovic N., Gonsalves M., et al. EAU guidelines on urological trauma. European Association of Urology, 2016. Режим доступа: <https://uroweb.org/individual-guidelines/non-oncology-guidelines/>. Дата обращения: 15.02.2022.
12. Cannis M., Mailhot T., Perera P. Bedside ultrasound in a case of blunt scrotal trauma // *West J Emergency Med*. 2013. Vol. 14, N 2. P. 127–129. doi: 10.5811/westjem.2012.8.12630
13. Bhatt S., Ghazale H., Dogra V.S. Sonographic evaluation of scrotal and penile trauma // *Ultrasound Clin*. 2007. Vol. 2, N 1. P. 45–56. doi: 10.1016/j.cult.2007.01.003
14. Pepe P., Panella P., Pennisi M., Aragona F. Does color Doppler sonography improve the clinical assessment of patients with acute scrotum? // *Eur J Radiol*. 2006. Vol. 60, N 1. P. 120–124. doi: 10.1016/j.ejrad.2006.04.016

- 15.** Muttarak M., Thinyu S., Lojanapiwat B. Clinics in diagnostic imaging (114). Rupture of the right testis // *Singapore Med J.* 2007. Vol. 48, N 3. P. 264–268.
- 16.** Yusuf G., Konstantatou E., Sellars M.E., et al. Multiparametric sonography of testicular hematomas: features on grayscale, color Doppler, and contrast-enhanced sonography and strain elastography // *J Ultrasound Med.* 2015. Vol. 34, N 7. P. 1319–1328. doi: 10.7863/ultra.34.7.1319
- 17.** Hedayati V., Sellars M.E., Sharma D.M., Sidhu P.S. Contrast-enhanced ultrasound in testicular trauma: role in directing exploration, debridement and organ salvage // *Br J Radiol.* 2012. Vol. 85, N 1011. P.e65–e68. doi: 10.1259/bjr/95600238
- 18.** Badea R., Lucan C., Suci M., et al. Contrast enhanced harmonic ultrasonography for the evaluation of acute scrotal pathology. A pictorial essay // *Med Ultrason.* 2016. Vol. 18, N 1. P. 110–115. doi: 10.11152/mu.2013.2066.181.esy
- 19.** Sidhu P.S., Cantisani V., Dietrich C.F., et al. The EFSUMB guidelines and recommendations for the clinical practice of contrast-enhanced ultrasound (CEUS) in non-hepatic applications: update 2017 (short version) // *Ultraschall Med.* 2018. Vol. 39, N 2. P. 154–180. doi: 10.1055/s-0044-101254
- 20.** Yusuf G.T., Rafailidis V., Moore S., et al. The role of contrast-enhanced ultrasound (CEUS) in the evaluation of scrotal trauma: a review // *Insights Imaging.* 2020. Vol. 11, N 1. P. 68. doi: 10.1186/s13244-020-00874-7
- 21.** Trinci M., Cirimele V., Ferrari R., et al. Diagnostic value of contrast-enhanced ultrasound (CEUS) and comparison with color Doppler ultrasound and magnetic resonance in a case of scrotal trauma // *J Ultrasound.* 2020. Vol. 23, N 2. P. 189–194. doi: 10.1007/s40477-019-00389-y
- 22.** Valentino M., Bertolotto M., Derchi L., et al. Role of contrast enhanced ultrasound in acute scrotal diseases // *Eur Radiol.* 2011. Vol. 21, N 9. P. 1831–1840. doi: 10.1007/s00330-010-2039-5
- 23.** Ramanathan S., Bertolotto M., Freeman S., et al. Imaging in scrotal trauma: a European Society of Urogenital Radiology Scrotal and Penile Imaging Working Group (ESUR-SPIWG) position statement // *Eur Radiol.* 2021. Vol. 31, N 7. P. 4918–4928. doi: 10.1007/s00330-020-07631-w

AUTHORS' INFO

* **Giuseppe Guglielmi**, MD, Professor;
address: Viale L. Pinto 1, 71121 Foggia, Italy;
ORCID: <http://orcid.org/0000-0002-4325-8330>;
e-mail giuseppe.guglielmi@unifg.it

Laura Eusebi, MD;
ORCID: <http://orcid.org/0000-0002-4172-5126>;
e-mail: lauraeu@virgilio.it

Maria T. Paparella, MD;
ORCID: <http://orcid.org/0000-0003-2573-9509>;
e-mail: mt.paparella@gmail.com

Andrea Marconi, MD;
ORCID: <http://orcid.org/0000-0002-6159-6376>;
e-mail: andreamarconi3@virgilio.it

05 ABTOPAX

* **Giuseppe Guglielmi**, MD, Professor;
адрес: Viale L. Pinto 1, 71121 Foggia, Italy;
ORCID: <http://orcid.org/0000-0002-4325-8330>;
e-mail giuseppe.guglielmi@unifg.it

Laura Eusebi, MD;
ORCID: <http://orcid.org/0000-0002-4172-5126>;
e-mail: lauraeu@virgilio.it

Maria T. Paparella, MD;
ORCID: <http://orcid.org/0000-0003-2573-9509>;
e-mail: mt.paparella@gmail.com

Andrea Marconi, MD;
ORCID: <http://orcid.org/0000-0002-6159-6376>;
e-mail: andreamarconi3@virgilio.it

* Corresponding author / Автор, ответственный за переписку